



## The role of an ophthalmologist in the Alström syndrome diagnosis

### Uloga oftalmologa u dijagnostici Alstromovog sindroma

Jelena Karadžić\*, Jelica Pantelić\*, Igor Kovačević\*, Marija Trenkić Božinović†

Clinical Centre Serbia, \*Eye Clinic, Belgrade, Serbia; Clinical Centre of Niš,

†Eye Clinic, Niš, Serbia

#### Abstract

**Introduction.** The Alström syndrome (AS) is an extremely rare autosomal recessive genetic disorder, affecting fewer than 1:1,000,000 people globally. It is a single gene disorder due to the mutation of *ALMS1* on chromosome 2 (2p13). The AS affects multiple organs and systems. Approximately 800 affected individuals have been identified worldwide so far. Some cases of the AS may go unrecognized for years as many of the clinical features develop over a longer period of time. As the nystagmus and retinitis pigmentosa are the most consistent findings, usually the first visible sign and present at the early infant period, the main aim of this article is to emphasize the importance of the ophthalmologist in establishing an adequate diagnosis of this rare syndrome.

**Case report.** This article describes a Serbian patient with the Alström syndrome, whose diagnosis was genetically confirmed using the whole exome sequencing. Our patient was a 7-year-old obese male with symptoms of progressive visual impairment, photophobia and nystagmus diagnosed in early childhood. On admission, the bilateral visual acuity was poor, RE 0.06, LE 0.01, the intraocular pressure within range. The funduscopy showed central retinal pigmentation,

thus suggesting cone-rod retinal dystrophy with “bull’s eye maculopathy”. The initial laboratory work at the time of the consultation revealed the elevated triglycerides levels and hyperinsulinemia, increased transaminases and gamma-glutamyl transpeptidase serum activity, whereas the glucose and glycated hemoglobin (HbA1C) levels were normal. The bilirubin test results were normal. Overall, the clinical manifestations were absent. The patient’s cardiac function was normal and the echocardiography did not indicate any abnormalities at the time. His sensorineural hearing was normal as well. A molecular genetic analysis was performed. Two composite heterozygous mutations were discovered within the *ALMS1* gene sequence. In addition to the clinical presentation, the mutation detection confirmed the initial diagnosis of the AS. **Conclusion.** The Alström syndrome should be kept in mind in case of an obese child with photophobia, nystagmus and visual impairment present from early childhood. Fundus examination by an ophthalmologist may significantly help to establish the diagnosis of this rare genetic syndrome.

#### Key words:

alstrom syndrome; diagnosis; ophthalmologists.

#### Apstrakt

**Uvod.** Alstromov syndrome (AS) je veoma retko autosomno recesivno oboljenje koje se javlja sa prevalencijom manjom od 1:1,000,000 ljudi širom sveta. To je oboljenje gena *ALMS1* na hromozomu 2 (2p13) koji utiče na više sistema organa. Do sada, oko 800 ljudi širom sveta ima dijagnostikovani AS. Neki slučajevi AS mogu da budu neprepoznati s obzirom na to da se mnoge kliničke karakteristike razvijaju tokom vremena. Kako su nistagmus i distrofija retine najdosledniji nalazi koji se obično pojavljuju prvi, u ranom detinjstvu, želimo da ukažemo na značaj oftalmologa u postavljanju dijagnoze ovog retkog sindroma. **Prikaz bolesnika.** U ovom radu, opisan je bolesnik sa Alstromovim sindromom čija dijagnoza je potvrđena genetskom analizom sekvenciranja celog egzoma. U pitanju je bio sedmogodišnji dečak, gojazan, sa simptomima progresivnog smanjenja vida, fotofobijom i nistagmusom koji su počeli u ranom detinjstvu. Početna

oština vida je bila na oba oka skromna, desno oko 0,06, levo oko 0,01, intraokularni pritisak u normalnim granicama. Na fundusu se videla centralna retinalna pigmentacija koja je ukazivala na *cone-rod* retinalnu distrofiju sa “bull’s eye maculopathy”. Laboratorijski nalazi su po blago povišene nivoe triglicerida. Glukoza i glikozilirani hemoglobin (HbA1C) su bili u normalnim granicama, ali je bila prisutna hiperinsulinemija. Takođe, aktivnosti transaminaza i gamaglutamil transpeptidaze u serumu su bili povišeni. Vrednosti bilirubina su bile u granicama referentnih vrednosti. Kardiološki i ehokardiografski nalazi su bili uredni. Rezultati ispitivanja sluha su bili u granicama referentnih vrednosti. Sprovedena je molekularna genetska analiza. Dve složene heterozigotne mutacije nađene su na *ALMS1* genu koje su, uz prisustvo kliničkih manifestacija, potvrdile dijagnozu AS. **Zaključak.** O Alstromovom sindromu treba razmišljati kada imamo gojazno dete sa fotofobijom, nistagmusom i smanjenjem vida koje datira od ranog detinjstva. Pregled fundusa od strane oftal-

mologa može da bude od velikog značaja i da podstakne sumnju na ovaj redak genetski sindrom.

**Ključne reči:**  
sindrom, almstrom; dijagnoza; oftalmoloji.

### Introduction

The Alström syndrome (AS) is an extremely rare autosomal recessive genetic disorder<sup>1</sup> affecting fewer than 1:1,000,000 people globally<sup>2</sup>. It is a single gene disorder, due to the mutation of *ALMS1* on chromosome 2 (2p13). The AS affects multiple organs and systems. The characteristic features of this syndrome are cone-rod retinal dystrophy causing juvenile blindness, hearing loss, truncal obesity, hyperinsulinemia and insulin resistance, type 2 diabetes mellitus (T2DM), hypertriglyceridemia, dilated cardiomyopathy, and progressive renal, pulmonary, hepatic and neurological dysfunction with mild seizure activity. These combinations of pathologies lead the patients to require multiple subspecialists appointments in order to prevent further complications<sup>3,4</sup>.

Approximately 800 affected individuals have been identified worldwide so far<sup>5</sup>. However, some cases of AS may go unrecognized or misdiagnosed as many of the clinical features develop over time, as the child grows. Also, there are wide clinical variations among the affected individuals<sup>6</sup>. That makes it difficult to determine the true frequency in the general population. The AS diagnosis is usually made on the basis of established clinical features, depending on the age of the patient<sup>7</sup>, often without genetic confirmation. However, in most cases the diagnosis is made retrospectively, usually in the first decade of life, after the development of various extraocular features<sup>8</sup>.

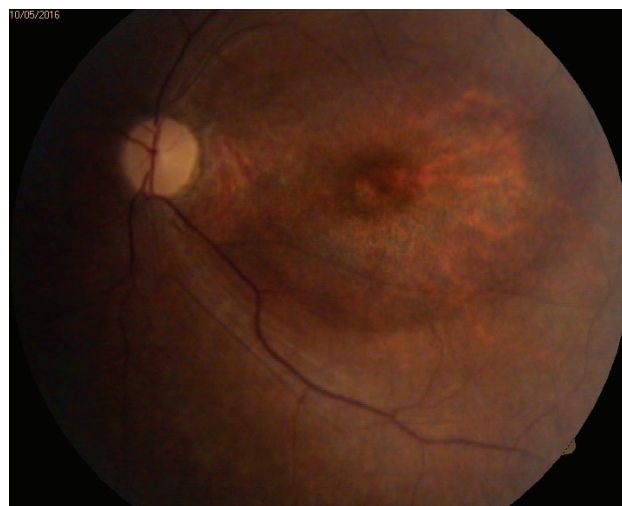
Since the nystagmus and retinitis pigmentosa are the most consistent findings, usually present first and in early childhood, the main aim of this article is to emphasize the importance of the ophthalmologist in establishing an adequate diagnosis of this rare syndrome. There are only two cases of the AS reported in Serbia<sup>3</sup>. In this study we want to present the third Serbian patient with the AS whose diagnosis was genetically confirmed using the whole exome sequencing.

### Case report

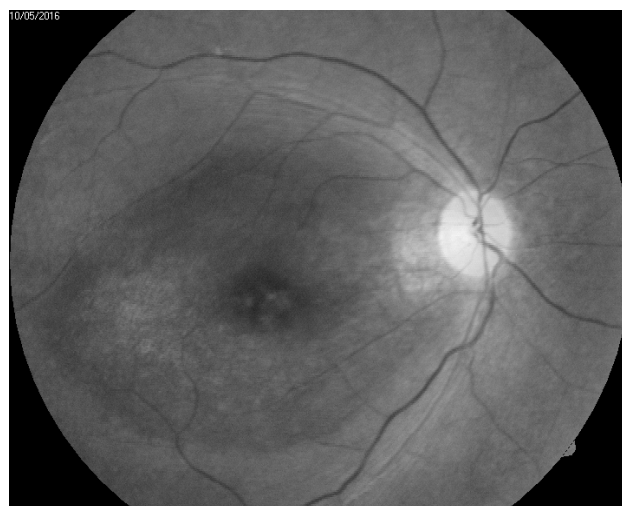
Our case was a 7-year-old male with symptoms of progressive visual impairment, photophobia and nystagmus noted from early childhood. His preliminary diagnosis was cone-rod retinal dystrophy. The patient was born as a second child of a two-child family, from a normal pregnancy and delivery. His family consists of non-related parents, both alive and healthy, and an older sister who is in good health.

This patient underwent the complete physical examinations including the ophthalmological, neurological, otorhinolaryngological and pediatric evaluations. The biochemical investigations as well as molecular genetic analysis were carried out. On admission, the bilateral visual acuity was poor, right eye (RE) 0.06, left eye (LE) 0.01, the in-

traocular pressure within range. In the neurological examination, both pupils were round in shape and midsize (3.5 mm), with a normal response to light. No abnormalities in the eye movements were detected except the horizontal nystagmus. The fundoscopy showed central retinal pigmentation, thus suggesting cone-rod retinal dystrophy with bull's eye maculopathy (Figures 1 and 2).

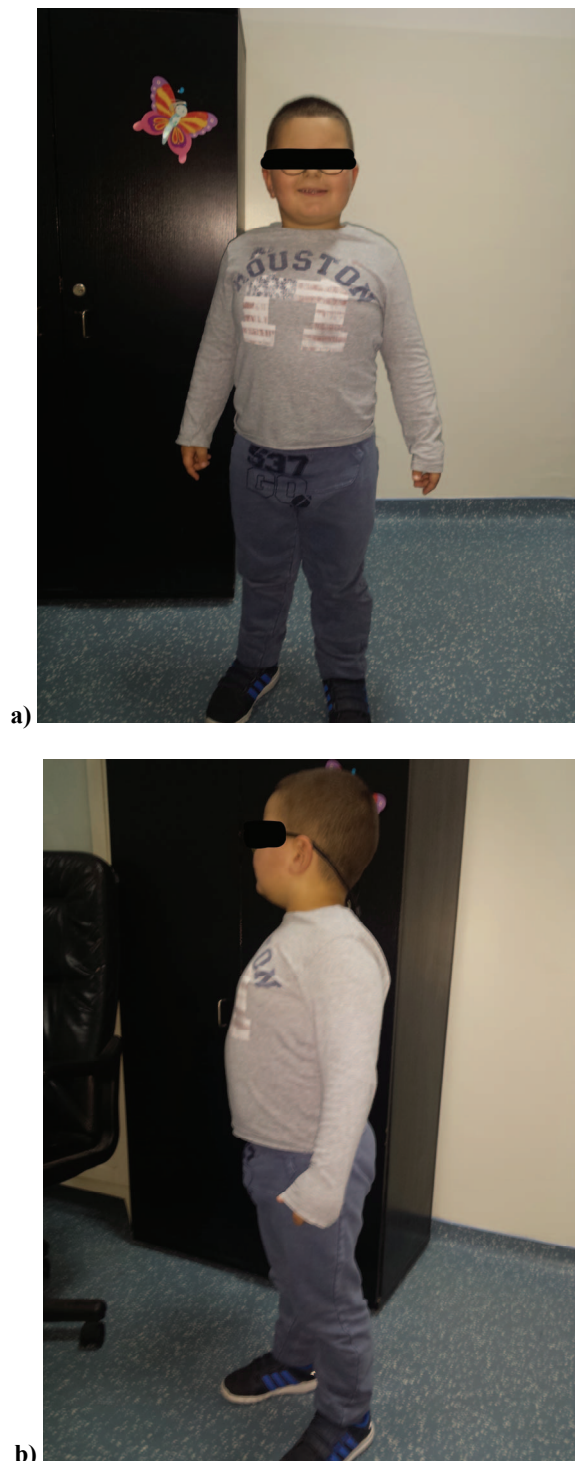


**Fig. 1 – Fundus photography of the left eye showing the “bull's eye maculopathy”.**



**Fig. 2 – Red free photography of the right eye showing the „bull's eye maculopathy“.**

In the physical examination, there was evidence of central obesity (Figure 3) with height being 119 cm, weight 36.9 kg, body mass index (BMI) 26,1 kg/m<sup>2</sup> (percentile > 98th) and waist circumference 78 cm. His cardiac function was normal as well as his sensorineural hearing. His blood pressure (BP) was 132/86 mmHg (percentile 95th) with a regular pulse of 80 beats per minute.



**Fig. 3 – Clinical pictures of a male boy with the Alström syndrome at the age of 7 years, presenting characteristic central obesity: a) characteristic round face; b) characteristic truncal obesity.**

The initial laboratory analyses at the time of the consultation revealed a slightly elevated triglycerides level 1.47 mmol/L (normal range 0.34–1.24) with a high density lipoprotein cholesterol (HDL-C) level of 0.99 mmol/L (normal range 1.04–1.55). His glucose and HbA1C levels were normal (4.7 mmol/L and 5%, respectively), while hyperinsulinemia was observed at 31 mU/L (normal < 10 mU/L). His

transaminases [aspartate transaminase (AST) and alanine transaminase (ALT)] and gamma-glutamyl transpeptidase (GGT) serum activities were elevated (AST 104U/L, ALT 247U/L, GGT 73U/L). The bilirubin test results were normal. Overall, the clinical manifestations were absent. The abdominal ultrasound showed evidence of steatosis, with normal liver and spleen measurements. Echocardiography did not indicate any pathology at the time. The blood urea nitrogen, creatinine and uric acid were normal. The renal echocardiography did not indicate any abnormalities. His current treatment was a low-fat diet and moderate exercise.

As a result of therapy, after six months, the triglyceride level decreased to 1.1 mmol/L, while HDL-C decreased to 0.93 mmol/L. Despite the diet correction, the child was not physically active. Adding physical activity helped him raise HDL cholesterol to 1.36 mmol/L at the next checkup.

Our patient underwent the molecular genetic analysis (Genetic Diagnostic Laboratory, Strasbourg University Hospitals, France). The coding sequences of exons 16 and 19 of *ALMS1* were polymerase chain reaction (PCR) amplified, purified and products were sequenced according to standard methods. The genetic samples were analyzed in order to characterize retinitis pigmentosa on the molecular plane. As a result, two composite heterozygous mutations were discovered in the gene *ALMS1*: two nucleotide variations in exons 16 and 19 of the gene *ALMS1*: c. [10569\_10570del]; [12047del], p. [His3523Glnfs\*17]; [Gly4016Alafs\*15]). A heterozygous *ALMS1* mutation detected in exon 16 and 19, together with the clinical picture, confirmed the AS diagnosis.

### Discussion

The aim of this article is to highlight the AS as one of the rarest genetic disorders in the world. This syndrome represents a ciliopathy that involves multiple organs and shares mutual clinical characteristics of blindness due to retinal dystrophy, early onset of obesity, diabetes and neurosensory deafness<sup>9,10</sup>. Although the specific role of the *ALMS1* protein has not yet been thoroughly investigated, it plays an important role in the cilia function and intraflagellar transport, allowing the AS to be classified as a ciliopathy<sup>11</sup>. Therefore, it is pertinent to distinguish the AS from other similar diseases accompanied by childhood obesity and retinal dystrophy, such as the Bardet-Biedl and Laurence-Moon syndromes. The cognitive impairment and distal digit abnormalities separate it from a more common ciliopathy, the Bardet-Biedl, while deafness and the absence of spastic paraparesis differentiate the AS from Laurence-Moon<sup>12</sup>. The exact etiology of the disease is unknown, but it is believed to be due to progressive multiorgan fibrosis that leads to organ failure, which is the major cause of morbidity and mortality in the AS<sup>6</sup>.

As some clinical features of AS do not become apparent until adolescence, an early diagnosis can be difficult in young children. The AS exhibits a great extent of clinical variability, thus creating difficulties for the general definition<sup>13</sup>. Marshall et al.<sup>14</sup> set the major and minor criteria according to ages, which help the physician set a diagnosis. On the other hand, a diagnosis of the AS could be confirmed at any age with the genetic analysis when two *ALMS1* muta-

tions were identified, or one mutated *ALMS1* allele found in the context of characteristic clinical signs<sup>10,14</sup>. Therefore, the genetic testing should be carried out in the patients who do not have all of the classic AS characteristics<sup>14</sup> and when the combination of the recommended criteria does not allow a clinical diagnosis<sup>7</sup>. There is no treatment that can cure the AS, prevent, and/or reverse the clinical features. The patients require a thorough initial assessment along with an intensive multidisciplinary approach and follow-ups in order to detect and treat potential complications<sup>7</sup>. Only an early diagnosis of the AS allows us a timely and preplanned management to avoid undesired complications and thus improve longevity as well as the quality of life of the patients<sup>15</sup>. The most common cause of death is hepatic dysfunction and congestive heart failure while life expectancy rarely exceeds 40 years<sup>7</sup>. Our patient was on a controlled diet and moderate physical exercise that usually lead to the reduction of the body mass index and better lipoprotein values<sup>16</sup>.

We suspected the AS in our patient according to the criteria from the second group<sup>7</sup>. The genetic results confirmed the reputed diagnosis of the AS, linked to the locus *ALMS1* previously rendered. The AS is autosomal recessive, so the parents of the affected child represent heterozygous carriers who do not show any signs of the disease. We assume that one of these mutations comes from the mother, while the other one probably from the father, but this was not con-

firmed since the father's sample was unavailable. The mutation of *ALMS1* gene causes cone-rod retinal dystrophy, which is part of the AS spectrum. The fundus examination gains ever-increasing importance because retinal dystrophy represents the earliest and most constant feature of the AS<sup>17</sup>. Still, retinal dystrophy is not isolated and is accompanied with multiple organ disorders mentioned above<sup>6,7</sup>. Therefore, the detailed multidisciplinary approach is recommended<sup>18</sup> including the biological exams such as liver and kidney biological functions, search for diabetes, insulin resistance, dyslipidemia, cardiological monitoring, search for deafness and overweight care. Prenatal and predictive diagnosis should be conducted if both mutated alleles are found in the parents<sup>14</sup>.

### Conclusion

In conclusion, the Alström syndrome should be kept in mind while examining an obese child with photophobia, nystagmus and visual impairment present from early childhood. Genetic analysis is quite difficult and expensive, so all patients with diabetes or truncal obesity are not able to apply. The fundus examination by an ophthalmologist can be of a significant help in pointing out the diagnosis of this rare genetic syndrome especially as there is no cure for this condition and detailed multidisciplinary approach is recommended in order to prevent further complications.

### R E F E R E N C E S

1. *Abmad A, Souza BD, Yadav C, Agarwal A, Kumar A, Nandini M, et al.* Metabolic Syndrome in Childhood: Rare Case of Alstrom Syndrome with Blindness. *J Clin Biochem* 2016; 31(4): 480–2.
2. *Minton JA, Owen KR, Ricketts CJ, Crabtree N, Shaikh G, Ebtisham S, et al.* Syndromic obesity and diabetes: Changes in body composition with age and mutation analysis of *ALMS1* in 12 United Kingdom kindreds with Alstrom syndrome. *J Clin Endocrinol Metab* 2006; 91(8): 3110–6.
3. *van Groenendaal S, Giacomazzi L, Davison F, Holtkemper O, Huang Z, Wang Q, et al.* High quality, patient centred and coordinated care for Alstrom syndrome: A model of care for an ultra-rare disease. *Orphanet J Rare Dis* 2015; 10: 149.
4. *Kuburović V, Marshall JD, Collin GB, Nykamp K, Kuburović N, Milenković T, et al.* Differences in the clinical spectrum of two adolescent male patients with Alström syndrome. *Clin Dysmorphol* 2013; 22(1): 7–12.
5. *Pagon RA, Adam MP, Ardinger HH, McDermott S.* Alström Syndrome. In: *Adam MP, Ardinger HH, Pagon RA, Wallace SE, Bean LJH, Stephens K, et al, editors.* GeneReviews®. Seattle (WA): University of Washington; 1993–2018.
6. *Marshall JD, Bronson RT, Collin GB, Nordstrom AD, Maffei P, Paisey RB, et al.* New Alström syndrome phenotypes based on the evaluation of 182 cases. *Arch Intern Med* 2005; 165(6): 675–83.
7. *Marshall JD, Beck S, Maffei P, Naggert JK.* Alström syndrome. *Eur J Human Gen* 2007; 15(12): 1193–202.
8. *Khan AO, Bifari IN, Bolz HJ.* Ophthalmic Features of Children Not Yet Diagnosed with Alstrom Syndrome. *Ophthalmology* 2015; 122(8): 1726–7.
9. *Girard D, Petrowsky N.* Alström syndrome: Insights into the pathogenesis of metabolic disorders. *Nat Rev Endocrinol* 2011; 7(2): 77–88.
10. *Forsythe E, Beales PL.* Bardet-Biedl syndrome. *Eur J Human Gen* 2013; 21(1): 8–13.
11. *Collin GB, Cyr E, Bronson R, Marshall JD, Gifford EJ, Hicks W, et al.* *ALMS1*-disrupted mice recapitulate human Alström syndrome. *Hum Mol Genet* 2005; 14(16): 2323–33.
12. *Budden SS, Kennaway NG, Buist NR, Poulos A, Weleber RG.* Dysmorphic syndrome with phytanic acid oxidase deficiency, abnormal very long chain fatty acids, and pipercolic acidemia: Studies in four children. *J Pediatr* 1986; 108(1): 33–9.
13. *Hoffman JD, Jacobson Z, Young TL, Marshall JD, Kaplan P.* Familial variable expression of dilated cardiomyopathy in Alström syndrome: A report of four sibs. *Am J Med Genet A* 2005; 135(1): 96–8.
14. *Marshall JD, Maffei P, Beck S, Barrett TG, Paisey RB, Naggert JK.* Clinical utility gene card for: Alstrom syndrome: update 2013. *Eur J Hum Genet* 2013; 21(11): doi: 10.1038/ejhg.2013.61.
15. *Tiwari A, Awasthi D, Tayal S, Ganguly S.* Alstrom syndrome: A rare genetic disorder and its anaesthetic significance. *Indian J Anaesth* 2010; 54(2): 154–6.
16. *Sente J, Jakonić D, Smajić M, Mihajlović I, Vasić G, Romanov R, et al.* Reduction of juvenile obesity by programmed physical exercise and controlled diet. *Vojnosanit Pregl* 2012; 69(1): 9–15. (Serbian)
17. *Álvarez-Satta M, Castro-Sánchez S, Valverde D.* Alström syndrome: Current perspectives. *Appl Clin Genet* 2015; 8: 171–9.
18. *Silan F, Gur S, Kadioglu LE, Yalcintepe SA, Ukinc K, Uludag A, et al.* Characteristic findings of alstrom syndrome with a case report. *Open J Clin Diagn* 2013; 3: 75–7.

Received on March 14, 2017.

Revised on September 13, 2017.

Accepted on October 24, 2017.

Online First November, 2017.